*Original Paper***Ameliorative effect of Coenzyme Q10 against liver oxidative stress induced by mercuric chloride in rat model**

Aya Gamal, Mohamed Abo Salem, Elham Elshewy, Ahmed M. Hegazy, Samar S Ibrahim

Forensic Medicine and Toxicology Department, Faculty of veterinary medicine, Benha University, Egypt.

**ARTICLE INFO****Keywords**

Coenzyme Q10  
 HgCl<sub>2</sub>  
 Mercuric residues  
 Oxidative stress

Received 22/11/2022

Accepted 14/12/2022

Available On-Line

15/01/2023

**ABSTRACT**

Mercury is given particular attention, because of its detrimental impacts on both human and animal health. It is claimed that it accumulates in the liver, causing liver toxicity and tissue damage. Consequently, it was intended in the current research to explore the potential antioxidant activity of coenzyme Q10 (CoQ10) against mercuric chloride (HgCl<sub>2</sub>)-induced hepatotoxicity. Twenty-eight male albino rats were divided into four groups: control group; given saline, CoQ10 group; given CoQ10 (10 mg/kg b.wt.); HgCl<sub>2</sub> group; given mercuric chloride (1 mg/kg b.wt.); and the co-treated group, given coenzyme Q10 (10 mg/kg b.wt.) plus HgCl<sub>2</sub> (1 mg/kg b.wt.). All treatments were received orally for 4 weeks. The HgCl<sub>2</sub> group had significantly higher serum concentrations of alanine aminotransferase, aspartate aminotransferase, alkaline phosphatase, and lactate dehydrogenase enzymes, while total protein and albumin values were significantly decreased. Rats also showed a significant increase in mercury concentration and exhibited a notable spike of lipid peroxidation levels with concurrent declines in antioxidant enzyme (GSH). This result was concomitant with histopathological changes of examined liver tissues. Treatment with Co-treatment with CoQ10 ameliorated the hepatotoxicity induced by HgCl<sub>2</sub> as indicated by improved serum biochemical parameters, oxidative markers, histopathological features of hepatic tissues. In conclusion, CoQ10 could be the best choice to counteract the liver toxicity produced by mercuric chloride exposure through its antioxidant effect.

**1. INTRODUCTION**

Mercury is one of the most harmful environmental toxic metals to both human and animal health (Rahman and Singh, 2019). Environmental exposure to mercury in its metallic, organic, and inorganic forms is a result of anthropogenic and natural sources including mining, incineration, volcanic activity, industrial wastewater discharge, and medical usage (Ye et al., 2016). Because of the element's volatility or some of its derivatives, mercury is known to be a poisonous, persistent, and mobile pollutant. In addition, it does not break down in the environment and can travel far within air masses (Pacyna et al., 2020).

Among the most dangerous forms of mercury is mercuric chloride (HgCl<sub>2</sub>), due to its ability to quickly permeate biological membranes and form organ-mercury complexes by binding with proteins (Joshi et al., 2017). Since HgCl<sub>2</sub> is weakly absorbed in the digestive tract, it is primarily eliminated in feces. It has been demonstrated that mercuric chloride is absorbed, goes through the cycle of hepatic biliary, also is released into the bile and then returns to the liver after being partially reabsorbed into the bloodstream (Kalender et al., 2013). Due to its ability to bind with protein and non-protein sulfhydryl complexes, HgCl<sub>2</sub> causes oxidative stress and a disequilibrium in the body's pro-oxidant and antioxidant defence mechanisms, which

lead to substantial amounts of reactive oxygen species (ROS) (Martinez et al., 2014).

Since the liver is essential for physiological metabolism as well as several detoxification functions, it serves as the body's primary organ for processing toxins (Zhang et al., 2017). According to numerous studies, exposure to HgCl<sub>2</sub> generates liver damage via a variety of complex pathways, such as oxidative stress, DNA damage, induction of the apoptotic pathway, as well as mitochondrial malfunction (Elblehi et al., 2019). In order to counteract these issues, researchers thought that using antioxidant compounds was a novel approach (Karuppanan et al., 2014; Mohamed, 2018).

Coenzyme Q10 (CoQ10) is a naturally existing antioxidant found in every organisms, its formed from benzoquinone ring with ten isoprenoid side chain (Rodick et al., 2018). It is found in organs with high energy demand and high mitochondrial content like the liver, kidney, and heart (Gutierrez-Mariscal et al., 2019). It is essential for the generation of ATP by transferring electrons from complexes I and II to complex III in the mitochondrial electron transport chain (Lee et al., 2017). Also, CoQ10 is considered a potent antioxidant in the inner mitochondrial membrane, either actively by removing free radicals or passively by reviving the active form of vitamins E and C (Gutierrez-Mariscal et al., 2019).

Numerous investigations have indicated that CoQ10 has an ameliorative effect against oxidative stress induced by

\* Correspondence to: aya307gamal@gmail.com

acute cadmium toxicity (Paunović *et al.*, 2017) and nephrotoxicity induced by lead by regenerating antioxidant activity (AL-Megrin *et al.*, 2020). Given CoQ10's ability to suppress inflammation, apoptosis and oxidative stress, it might be a potential therapeutic approach (Yousef *et al.*, 2019). Therefore, this research was conducted to investigate into the preferential impacts of CoQ10 supplementation against HgCl<sub>2</sub>-induced liver oxidative stress damage.

## 2. MATERIAL AND METHODS

### 2.1. Chemicals:

Sigma Aldrich Co., USA provided the pure form of mercury chloride (HgCl<sub>2</sub>, 99%) (Cat #M1136). Coenzyme Q 10® was obtained from MEPACO in Cairo, Egypt.

### 2.2. Animals and experimental design:

Twenty-eight male albino rats, weighing 130–150 g, were used in the current investigation. The Animal Laboratory at the Faculty of Veterinary Medicine, Benha University, Egypt donated them. Rats were acclimatized for 2 weeks before the experiment in a standard laboratory setting with an ambient temperature of 25°C and receiving pelleted rodent food and unlimited amounts of water. This study was approved by the Ethics Committee, Faculty of Veterinary Medicine, Benha University (Ethical Approval No. BUFVTM 19.03.22).

The rats were randomly divided into 4 group (7 per each group) as following:

Group1: deal as vehicle control received physiological saline at dose 1 ml/ kg b.wt.

Group2: rats were given CoQ10 at dose10 mg/kg b.wt. (Chen *et al.*, 2017).

Group3: rats were administrated HgCl<sub>2</sub> at dose 1 mg/ kg b.wt. (Aslanturk *et al.*, 2014)

Group4: deal as co-treated group, received CoQ10 one hour before HgCl<sub>2</sub> (at dose10 mg/kg b.wt.) and HgCl<sub>2</sub> (1 mg/ kg b.wt.).

All treatments were applied orally for 4 weeks per day.

Animals were weighed after the treatment period, euthanized under mild ether (Othman *et al.*, 2014), and then blood samples were gathered in dry, clean test tubes for serum separation and was kept at -20 °C to evaluate biochemical indices. Wet weight was measured after the liver tissues separation from the surrounding tissue. Using the following formula:

$\text{Organ weight} / \text{body weight} \times 100$ , the relative organ weight of the liver was then determined.

After that, the liver split into two portions. One was soaked in paraformaldehyde solution for histopathological analysis, and the other portion in ice-cold phosphate-buffered saline (PBS) for antioxidant evaluation.

### 2.3. Biochemical assays:

#### 2.3.1. Evaluation serum biochemical markers of liver functions

The activities of ALT, AST, ALP, LDH, albumin and total protein levels were assessed in collected sera according to former authors (Bergmeyer *et al.*, 1986; Randox, 2011; Kumar and Gill, 2018) by using commercial kits((Spectrum Diagnostics company, cairo, Egypt) and following strictly the instructions issued by the manufacturers.

Table 1 Effect of COQ10 on absolute and relative liver weight of HgCl<sub>2</sub> treated rats:

Groups	Liver weight		Body weight	
	Absolute (g)	Relative (g/100g)	Initial	Final
Control	10.17±.62 <sup>a</sup>	3.61± .12	154.43±17.51	286.43±23.85 <sup>a</sup>
CoQ10	8.25±.29 <sup>b</sup>	3.45 ±.11	129±8.65	240.72±10.88 <sup>a,b</sup>
HgCl <sub>2</sub>	3.38 ±.21 <sup>c</sup>	2.95 ±.48	131.71±6.04	126.5±12.65 <sup>c</sup>
CoQ10+ HgCl <sub>2</sub>	7.17±.38 <sup>b</sup>	3.37±.19	143.43±4.94	215±12.91 <sup>b</sup>

Data are presented as the mean ± SE (n = 7). Means with different superscript within the same row.

#### 2.3.2 Assessment the oxidative markers:

The MDA concentration in hepatic tissue homogenate was measured according to method Uchiyama & Mihara (1978), and liver antioxidants; reduced glutathione (GSH); as described by Beutler *et al.* (1963) were measured using specialized diagnostic kits obtained from the Laboratory Bio Diagnostic Company Bio Diagnostic Company, Giza, Egypt.

#### 2.3.3 Assessment of mercury residue in liver tissue:

Mercury residues in liver tissue homogenate were evaluated using atomic absorption spectrometry (AAS) in accordance with the procedure described by Seady *et al.* (2001). Acid digestion solution in 5 ml (3 ml HNO<sub>3</sub>; 2 ml HClO<sub>4</sub>) were added to each gram of samples, left for the length of the night at room temperature. To ensure the samples' thorough digestion, the water bath was heated for three hours at 70 °C. The resultant clear homogenates were kept at room temperature, adjusted with 20 ml of deionized water, and then filtered through filter paper (Watt man No. 42). Samples and standards were contrasted within the linear range of the calibration.

#### 2.3.4. Histopathological evaluation:

Small tissue specimens were collected from liver of rats in all groups and immediately fixed in 10% formalin. Then 5-µm thickness sections were routinely prepared, and stained by hematoxylin and eosin (H&E) for light microscopy analysis (Bancroft and Gamble, 2008)

#### 2.3.5. Statistical analysis data:

Statistical analysis of the experimental results was carried out using SPSS (Version 20; SPSS Inc., Chicago, USA). One-way ANOVA was performed to estimate the differences between the groups, and the Duncan test was employed as the post hoc analysis. Values were presented as Mean ± standard error, with a P-value of ≤ 0.05 indicated a significant difference.

## 3. RESULTS

#### 3.1. Effect of CoQ10 and/or HgCl<sub>2</sub> on absolute and relative weight of liver:

HgCl<sub>2</sub> significantly reduced absolute liver weight compared to the CoQ10, control, as well as co-treated groups. pretreatment with CoQ10 (in HgCl<sub>2</sub>+ CoQ10 group) significantly (p< 0.05) improved the values of absolute liver weight. Moreover, the relative liver weight was unchanged across all groups (p> 0.05). When compared to the control group, body weight dramatically dropped in the HgCl<sub>2</sub> group, but significantly (p< 0.05) elevated in the HgCl<sub>2</sub>+ CoQ10 group compared to the HgCl<sub>2</sub> group (Table 1).

#### 3.2. Effect of CoQ10 and/or HgCl<sub>2</sub> on serum biochemical liver parameters:

As illustrated in figure (1), HgCl<sub>2</sub> induced hepatotoxicity as indicated by increasing serum liver biomarkers (AST, ALT, ALP, and LDH) than those of the control and CoQ10 groups

While the activities of such parameters were lowered in the HgCl<sub>2</sub>+ CoQ10 group in relation to HgCl<sub>2</sub> group (p< 0.05). Substantially lower amounts of total protein and albumin after receiving HgCl<sub>2</sub>. In contrast, the total protein and albumin were noticeably improved in the HgCl<sub>2</sub>+CoQ10 group in relative to the HgCl<sub>2</sub> group (p< 0.05).

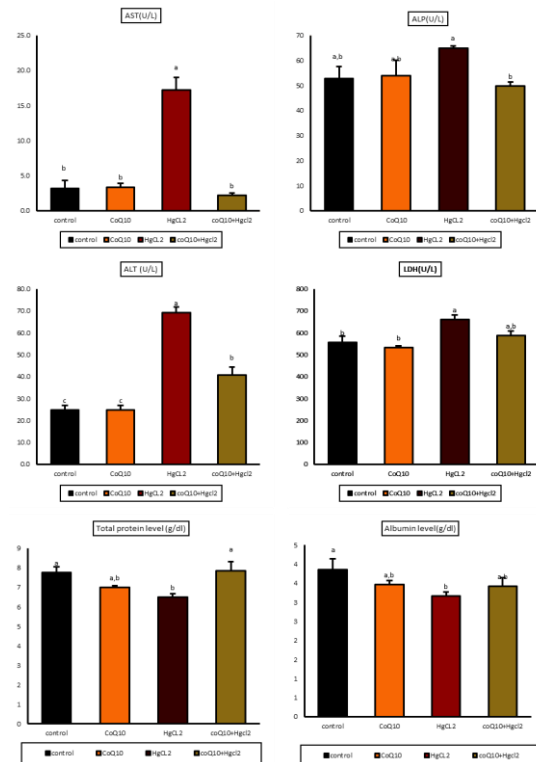


Figure 1 Effect of CoQ10 and/or HgCl<sub>2</sub> on serum biochemical liver parameters of treated rats. All data are expressed as the mean ± SE, n = three. Superscript letters in the same row indicate a statistically significant difference (P ≤ 0.05).

3.3. Effect of CoQ10 and/or HgCl<sub>2</sub> on liver oxidative stress

As showed in figure (2), HgCL<sub>2</sub> induced hepatic oxidative stress confirmed by significantly increase in MDA levels and significantly decline in GSH levels. Concurrent CoQ10 therapy considerably reduced the oxidative damage brought on by mercury. The HgCl<sub>2</sub>+ CoQ10 group in particular showed a considerable improvement.

3.4 Effect of CoQ10 and/or Hgcl2 on mercury residue in liver tissues:

According to figure (2), there was a significant increase of mercury residues in HgCl<sub>2</sub> group in relative to control group, while CoQ10 supplementation significantly decrease mercury accumulation in liver tissue in compared to the HgCl<sub>2</sub> group (p< 0.05).

3.5. Impacts of CoQ10 and/or Hgcl2 on hepatic histopathological changes:

As shown in figure (3), the examined liver of rats in control and CoQ10 group had regular distributed of hepatocytes forming hepatic cords. Whereas, HgCl<sub>2</sub> treatment induced hepatic damage evidenced by irregular distribution of hepatic cords with pyknotic nuclei and vacuolated cytoplasm of hepatocytes, congestion of central veins and perivascular mononuclear cellular aggregation, fibrosis, and dilated blood vesseles were seen. Area of portal vien show a sever congestion suurounded by cellular infiltration. On the other hand, CoQ10 +HgCl<sub>2</sub> treatment appeared

improvement of histoarchitecture of liver tissues more or less like control group.

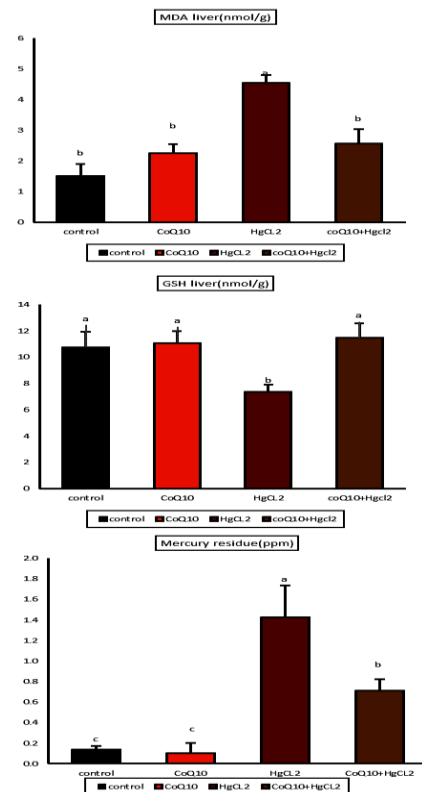


Figure 2 Effect of CoQ10 and/or HgCl<sub>2</sub> on hepatic lipid peroxidation (MDA), antioxidant parameter (GSH), and mercury accumulation of treated rats. All data are expressed as the mean ± SE, n = three. Superscript letters in the same row indicate a statistically significant difference (P ≤ 0.05).

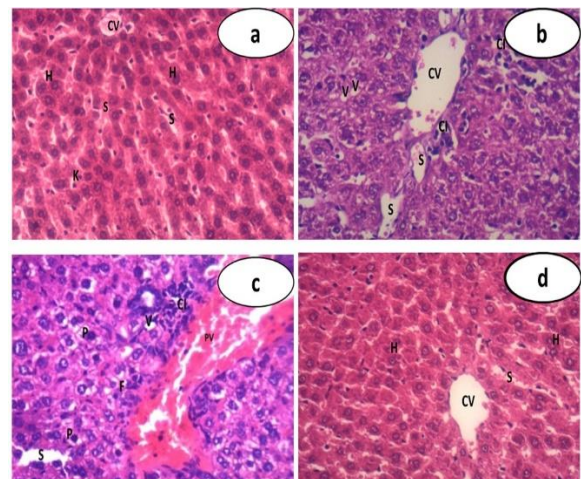


Figure 3 Effect of HgCl<sub>2</sub> and/or CoQ10 on liver histopathology in treated rats. A: liver tissue from the control and CoQ10 groups show regularly arranged hepatocytes (H) forming hepatic cords around a central vein (CV) lined with flat endothelium (×400). B and C: HgCl<sub>2</sub> treated group, respectively, showing highly distributed irregular pattern of hepatic cords with congestion of central vein (CV) and perivascular mononuclear infiltration, dilated congested portal vein ruptured from different areas (PV) that surrounded by cellular infiltration (CI), fibrosis, dilated blood sinusoid (S) and vacuolation of the cytoplasm (V) with pyknotic nuclei of hepatocytes (P) (×400). D: The co-treated group exhibit improvement of the histological picture in the form of regularly arranged hepatocytes (H) forming hepatic cords around a central vein (CV) separated by blood sinusoid (S) more or less like control group (H&E, ×400).

4. DISCUSSION

Mercury is the third-most dangerous heavy metal in regards of its toxicity, and because of its detrimental physiological and pathological effects, it poses serious health risks (Othman et al., 2014). Exposure of human and animals to

mercury toxicity in any of its forms by multiple routes like ingestion, inhalation or dermal because it extensively dispersed in the environment (Kim et al., 2016). According to the experimental data that is currently available, the buildup of HgCl<sub>2</sub> in the liver causes oxidative stress, and glutathione reduction because intracellular mercury interferes with activities of enzymes, impairing ATP and protein synthesis (Joshi et al., 2017). Consequently, it has been proposed in the current study that the antioxidant can assist in mitigating the detrimental effect of mercury exposure.

In toxicological studies, alterations in organ weight are among the main criteria for assessing organ toxicity, and reductions in body weight are represented as a signal for the rat's general health status to deteriorate. In this investigation, rats treated with HgCl<sub>2</sub> appeared significantly lose body weight gain in compared to control animals, as mentioned earlier (Uzunhisarcikli et al., 2016). Loss in weight, which is known as the main sign of mercury toxicity, has been associated with animals eating less food (Jaiswal et al., 2013). While the absolute and relative liver weight of HgCl<sub>2</sub> treated rats was significantly decreased in comparison to the control group, those results were consistent with prior reports (Abarikwu et al., 2018). However, our finding in contrast with those of Abarikwu et al. (2017), who found that HgCl<sub>2</sub> administration (5 mg/kg, ip, three times per week) for 21 days, not affected body weight and liver weight. whereas, the CoQ10-treated group with HgCl<sub>2</sub> was able to maintain body weight and liver weight.

The present finding showed that HgCl<sub>2</sub> induced hepatotoxicity was evidenced by biochemical and histopathological changes. Exposure to HgCl<sub>2</sub> caused significantly increased of transaminases (ALT, AST, ALP and LDH) enzymes in HgCl<sub>2</sub> group. These enzymes are potential indicator of hepatocellular injury and dysfunction. Owing to hepatic necrosis which changed the cell membrane's permeability (Joshi et al., 2017), and may be causing releasing of the liver enzymes from cytoplasm into blood. These results consistent with prior studies (Caglayan et al., 2019). LDH enzyme is crucial for recycling NAD<sup>+</sup> during anaerobic respiration so that glycolysis can continue (Shi and Pinto, 2014). Impairment of ATP production as HgCl<sub>2</sub> exposure that shift glucose metabolism from aerobic to anaerobic glycolysis which may explain the significant increase of serum LDH. The reduction in the serum total protein, and albumin levels in HgCl<sub>2</sub> group. The most prevalent plasma protein synthesised in the liver is albumin. The liver's production or metabolism of proteins are impacted by HgCl<sub>2</sub> (Uzunhisarcikli et al., 2016).

While serum hepatic function indicators (ALT, ALP, AST, total protein, and albumin) developed in the CoQ10-treated group with HgCl<sub>2</sub>. This indicates that CoQ10 has the propensity to prevent liver injury, hence preventing the leakage of enzymes across membranes and exhibiting hepato-protective effects. In response to CoQ10 treatment, serum LDH levels return to normal, which may be attributable to CoQ10's part in ATP synthesis, which shifts glucose metabolism into aerobic glycolysis.

The HgCl<sub>2</sub> group displayed hepatic injury in the form of hepatocellular necrosis, dilated blood vessels, and an uneven distribution of hepatic cords with pyknotic nuclei, perivascular mononuclear cellular aggregation. Parallel results were shown in earlier investigation (Caglayan et al., 2019). Conversely, the hepatic lesions in the CoQ10+ HgCl<sub>2</sub> co-treated rats improved more or less in line with the control group. Our findings were in agreement with those of Mwaeni et al., (2021), who discovered that oral

administration of CoQ10 (200 mg/kg, for 15 days) and continued with arsenate (15 mg/kg, for a further 30 days) alleviated the elevation of biomarkers enzymes of livers and histopathological changes of hepatic tissues caused by arsenic poisoning.

The degree of liver damage is connected with the intensity of intracellular and extracellular oxidative stress, which is based on an excessive synthesis of free radicals and an insufficient concentration of antioxidants (El-Sayed et al., 2015). Our findings showed that the HgCl<sub>2</sub> treatment substantial elevation the levels of lipid peroxidation (MDA), while significant reduction in the levels of antioxidant as reduced glutathion (GSH) in liver tissues. GSH serves as first line of cellular protection against Hg poisoning. The level of GSH in the cell decreased as a result of Hg<sup>2+</sup> binding to it, which diminished its antioxidant power and increased the degree of oxidative damage in the hepatic tissues (Mohamed, 2018). Our findings were confirmed by an increase in mercury concentration within hepatocytes, which causes oxidative stress and subsequent liver damage. our findings were agreed with several previous studies (Elblehi et al., 2019; Alhusaini et al., 2021; Raeszadeh et al., 2021).

CoQ10 acts a naturally occurring part of the electron transport chain, acts as a mobile redox agent involved in oxidative phosphorylation process for ATP synthesis (Lee et al., 2017). CoQ10 is regarded as a special mitochondrial antioxidant because it depletes the production of NADPH oxidase, a large source of oxygen (Ratliff et al., 2016). It slows the progression of lipid peroxidation by preventing its onset and development as well as replenishing vitamin E from alpha tocopheroxyl radicals (Varela-López et al., 2016).

In light of this, treatment with CoQ10 brought considerable protection against oxidative stress caused by HgCl<sub>2</sub> as evidenced by improvements in biochemical parameters, mercury accumulation and histopathological changes in the hepatic tissues. These changes might be due to marked enhancement of levels of GSH as well as decreased MDA because of the ROS-scavenging activity of CoQ10.

Our finding concur with those obtained from Eftekhari et al. (2018), who discussed that CoQ10 may be useful in preventing mitochondrial dysfunction and oxidative damage caused by dichlorvos in hepatic tissue. This preventative measure was in line with our finding. Moreover, CoQ10 reduced the production of ROS and MDA while also increasing GSH levels. In a separate investigation, Khalifa et al. (2020) found that CoQ10 protects against kidney damage induced by cisplatin, where CoQ10 increased the activities of CAT and SOD, increased GSH levels, and decreased MDA caused by cisplatin in renal tissue.

The protective effect of CoQ10 against piroxicam (PM) - mediated hepatotoxicity was also noted in a subsequent investigation by Abdeen et al. (2020), who showed that the CoQ10 supplementation reduced the detrimental hepatic oxidative damage and apoptosis caused by PM. Also this study, was consistence with our result.

## 5. CONCLUSION

According to the current study, Coenzyme Q10's antioxidant properties alleviate oxidative stress-induced liver damage. Moreover, our investigation suggested that the use of CoQ10 like a novel therapeutic for HgCl<sub>2</sub> induced hepatic damage through amelioration serum biomarkers of liver tissues, hepatic oxidative damage,

pathological changes of liver tissues and mercury accumulation in liver tissues.

## . REFERENCES

1. Abarikwu, S.O., Njoku, R.C.C., Onuah, C.L., 2018. Aged coconut oil with a high peroxide value induces oxidative stress and tissue damage in mercury-treated rats. *J. Basic Clin. Physiol. Pharmacol.* 29, 365–376.
2. Abdeen, A., Abdelkader, A., Elgazzar, D., Aboubakr, M., Abdulah, O.A., Shoghy, K., Abdel-Daim, M., El-Serehy, H.A., Najda, A., El-Mleeh, A., 2020. Coenzyme Q10 supplementation mitigates piroxicam-induced oxidative injury and apoptotic pathways in the stomach, liver, and kidney. *Biomed. Pharmacother.* 130, January, 110627.
3. AL-Megrin, W.A., Soliman, D., Kassab, R.B., Metwally, D.M., Dina, D.M., El-Khadragy, M.F., 2020. Coenzyme Q10 Activates the Antioxidant Machinery and Inhibits the Inflammatory and Apoptotic Cascades Against Lead Acetate-Induced Renal Injury in Rats. *Front. Physiol.* 11, 1–13.
4. Alhusaini, A., Alghilani, S., Alhuqbani, W., Hasan, I.H., 2021. Vitamin E and Lactobacillus Provide Protective Effects Against Liver Injury Induced by HgCl<sub>2</sub>: Role of CHOP, GPR87, and mTOR Proteins. *Dose-Response* 19,2, 155932582110113.
5. Aslanturk, A., Uzunhisarcikli, M., Kalender, S., Demir, F., 2014. Sodium selenite and vitamin E in preventing mercuric chloride induced renal toxicity in rats. *Food Chem. Toxicol.* 70, 185–190.
6. Bancroft, J.D., Gamble, M.B.T.-T. and P. of H.T. (Sixth E., 2008. *Managing the Laboratory*, in: Bancroft, J.D., Gamble, M.B.T.-T. and P. of H.T. (Sixth E. (Eds.), *Theory and Practice of Histological Techniques*. Elsevier, Edinburgh, Pp. 1–10.
7. Bergmeyer, H.U., Hørder, M., Rej, R., 1986. International Federation of Clinical Chemistry (IFCC) Scientific Committee, Analytical Section: approved recommendation (1985) on IFCC methods for the measurement of catalytic concentration of enzymes. Part 3. IFCC method for alanine aminotransferase (L-. *J. Clin. Chem. Clin. Biochem. Zeitschrift fur Klin. Chemie und Klin. Biochem.* 24, 481–495.
8. Beutler, E., Duron, O., Kelly, B.M., 1963. Improved method for the determination of blood glutathione. *J. Lab. Clin. Med.* 61, 882–888.
9. Caglayan, C., Kandemir, F.M., Darendelioglu, E., Yildirim, S., Kucukler, S., Dortbudak, M.B., 2019. Rutin ameliorates mercuric chloride-induced hepatotoxicity in rats via interfering with oxidative stress, inflammation and apoptosis. *J. Trace Elem. Med. Biol.* 56, 60–68.
10. Chen, P.-Y., Hou, C.-W., Shibu, M.A., Day, C.H., Pai, P., Liu, Z.-R., Lin, T.-Y., Viswanadha, V.P., Kuo, C.-H., Huang, C.-Y., 2017. Protective effect of Co-enzyme Q10 On doxorubicin-induced cardiomyopathy of rat hearts. *Environ. Toxicol.* 32, 679–689.
11. Eftekhari, A., Ahmadian, E., Azami, A., Johari-Ahar, M., Eghbal, M.A., 2018. Protective effects of coenzyme Q10 nanoparticles on dichlorvos-induced hepatotoxicity and mitochondrial/lysosomal injury. *Environ. Toxicol.* 33, 167–177.
12. El-Sayed, Y.S., Lebda, M.A., Hassinin, M., Neoman, S.A., 2015. Chicory (*Cichorium intybus* L.) root extract regulates the oxidative status and antioxidant gene transcripts in CCl<sub>4</sub>-induced hepatotoxicity. *Plos One* 10, 10,3, 1–12.
13. Elblehi, S.S., Hafez, M.H., El-Sayed, Y.S., 2019. L- $\alpha$ -Phosphatidylcholine attenuates mercury-induced hepato-renal damage through suppressing oxidative stress and inflammation. *Environ. Sci. Pollut. Res.* 26, 9333–9342.
14. Gutierrez-Mariscal, F.M., Yubero-Serrano, E.M., Villalba, J.M., Lopez-Miranda, J., 2019. Coenzyme Q10: From bench to clinic in aging diseases, a translational review. *Crit.Rev.Food Sci. Nutr.* 59, 2240–2257.
15. Jaiswal, N., Kumar, D., Rizvi, S.I., 2013. Red onion extract (*Allium cepa* L.) supplementation improves redox balance in oxidatively stressed rats. *Food Sci. Hum. Wellness* 2, 99–104.
16. Joshi, D., Srivastav, S.K., Belemkar, S., Dixit, V.A., 2017. Zingiber officinale and 6-gingerol alleviate liver and kidney dysfunctions and oxidative stress induced by mercuric chloride in male rats: A protective approach. *Biomed. Pharmacother.* 91, 645–655.
17. Kalender, S., Uzun, F.G., Demir, F., Uzunhisarcikli, M., Aslanturk, A., 2013. Mercuric chloride-induced testicular toxicity in rats and the protective role of sodium selenite and vitamin E. *Food Chem. Toxicol. an Int. J. Publ. Br. Ind. Biol. Res. Assoc.* 55, 456–462.
18. Karuppanan, M., Krishnan, M., Padarathi, P., Namasivayam, E., 2014. Hepatoprotective and Antioxidant Effect of Mangifera Indica Leaf Extracts against Mercuric Chloride-induced Liver Toxicity in Mice. *Euroasian J. Hepato-Gastroenterology* 4, 18–24.
19. Khalifa, E.A., Nabil Ahmed, A., Hashem, K.S., Allah, A.G., 2020. Therapeutic Effects of the Combination of Alpha-Lipoic Acid (ALA) and Coenzyme Q10 (CoQ10) on Cisplatin-Induced Nephrotoxicity. *Int. J. Inflamm.* 2020. 1-11
20. Kim, K.H., Kabir, E., Jahan, S.A., 2016. A review on the distribution of Hg in the environment and its human health impacts. *J. Hazard. Mater.* 306, 376–385.
21. Kumar, V., Gill, K.D., 2018. Determination of Total Lactate Dehydrogenase Activity in Serum Sample, in: Kumar, V., Gill, K.D. (Eds.), *Basic Concepts in Clinical Biochemistry: A Practical Guide*. Springer Singapore, Singapore, Pp. 129–130.
22. Lee, S.Q.E., Tan, T.S., Kawamukai, M., Chen, E.S., 2017. Cellular factories for coenzyme Q10 production. *Microb. Cell Fact.* 16, 1–16.
23. Martinez, C.S., Torres, J.G.D., Peçanha, F.M., Anselmo-Franci, J.A., Vassallo, D. V., Salaces, M., Alonso, M.J., Wiggers, G.A., 2014. 60-Day chronic exposure to low concentrations of hgcl2 impairs sperm quality: Hormonal imbalance and oxidative stress as potential routes for reproductive dysfunction in rats. *Plos One* 9, 11,1-9.
24. Mohamed, 2018. Protective effect of origanum oil on alterations of some trace elements and antioxidant levels induced by mercuric chloride in male rats. *Biol. Trace Elem. Res.* 182, 49–56.
25. Mohamed, N.E.-S., 2018. Protective Effect of Origanum Oil on Alterations of Some Trace Elements and Antioxidant Levels Induced by Mercuric Chloride in Male Rats. *Biol. Trace Elem. Res.* 182, 49–56.
26. Mwaeni, V.K., Nyariki, J.N., Jillani, N., Omwenga, G., Ngugi, M., Isaac, A.O., 2021. Coenzyme Q10 protected against arsenite and enhanced the capacity of 2,3-dimercaptosuccinic acid to ameliorate arsenite-induced toxicity in mice. *BMC Pharmacol. Toxicol.* 22, 1–19.
27. Nowotny, A., 1979. Protein Determination by the Biuret Method, in: Nowotny, A. (Ed.), *Basic Exercises in Immunochemistry*. Springer Berlin Heidelberg, Berlin, Heidelberg, pp. 168–169.
28. Othman, M.S., Safwat, G., Aboulkhair, M., Abdel Moneim, A.E., 2014. The potential effect of berberine in mercury-induced hepatorenal toxicity in albino rats. *Food Chem. Toxicol.* 69, 175–181.
29. Pacyna, J.M., 2020. Recent advances in mercury research. *Sci. Total Environ.* 738, 139955.
30. Paunović, M.G., Matic, M.M., Ognjanović, B.I., Saičić, Z.S., 2017. Antioxidative and haematoprotective activity of coenzyme Q10 and Vitamin E against cadmium-induced oxidative stress in Wistar rats. *Toxicol. Ind. Health* 33, 746–756.
31. Raeeszadeh, M., Moradi, M., Ayar, P., Akbari, A., 2021. The Antioxidant Effect of Medicago sativa L. (Alfalfa) Ethanolic Extract against Mercury Chloride (HgCl<sub>2</sub>) Toxicity in Rat Liver and Kidney: An In Vitro and In Vivo Study. Evidence-based Complement. *Altern. Med.* 2021, 1–10.
32. Rahman, Z., Singh, V.P., 2019. The relative impact of toxic heavy metals (THMs) (arsenic (As), cadmium (Cd), chromium (Cr)(VI), mercury (Hg), and lead (Pb)) on the total environment: an overview. *Environ. Monit. Assess.* 191,7,419.
33. Ratliff, B.B., Abdulmahdi, W., Pawar, R., Wolin, M.S., 2016. Oxidant mechanisms in renal injury and disease. *Antioxidants Redox Signal.* 25, 119–146.
34. Rodick, T.C., Seibels, D.R., Babu, J.R., Huggins, K.W., Ren, G., Mathews, S.T., 2018. Potential role of coenzyme Q10 in health and disease conditions. *Nutr. Diet. Suppl.* 10, 1–11.
35. Seady, N.I., 2001. Evaluated of heavy metals in meats and offal of various animal species slaughtered in menoufia governorate. PhD thesis, Faculty of Veterinary Medicine,

- Moshtohor, Zagazig University, Benha Branch.
36. Shi, Y., Pinto, B.M., 2014. Human Lactate Dehydrogenase A Inhibitors: A Molecular Dynamics Investigation. *PLoS One* 9, e86365
  37. Sunny O. Abarikwu\*, Sussan Benjamin, Sunday Godspower Ebah, G.O. and G.A., 2017. Protective effect of Moringa oleifera oil against HgCl<sub>2</sub>-induced hepato-and nephro-Toxicity in rats. *J. Basic Clin. Physiol. Pharmacol.* 28, 4,337–345
  38. Uchiyama, M., Mihara, M., 1978. Determination of malonaldehyde precursor in tissues by thiobarbituric acid test. *Anal. Biochem.* 86, 271–278.
  39. Uzunhisarcikli, M., Aslanturk, A., Kalender, S., Apaydin, F.G., Bas, H., 2016. Mercuric chloride induced hepatotoxic and hematologic changes in rats. *Toxicol. Ind. Health* 32, 9,1651–1662.
  40. Varela-López, A., Giampieri, F., Battino, M., Quiles, J., 2016. Coenzyme Q and Its Role in the Dietary Therapy against Aging. *Molecules* 21, 3,373.
  41. Ye, B.J., Kim, B.G., Jeon, M.J., Kim, S.Y., Kim, H.C., Jang, T.W., Chae, H.J., Choi, W.J., Ha, M.N., Hong, Y.S., 2016. Evaluation of mercury exposure level, clinical diagnosis and treatment for mercury intoxication. *Ann. Occup. Environ. Med.* 28,1, 1–8.
  42. Yousef A.S., A. Fahad, A., Abdel Moneim, A.E., Metwally, D.M., El-khadragy, M.F., Kassab, R.B., 2019. The Neuroprotective Role of Coenzyme Q10 Against Lead Acetate-Induced Neurotoxicity Is Mediated by Antioxidant, Anti-Inflammatory and Anti-Apoptotic Activities. *Int. J. Environ. Res. Public Health* 16, 16,2895.
  43. Zhang, H., Tan, X., Yang, D., Lu, J., Liu, B., Baiyun, R., Zhang, Z., 2017. Dietary luteolin attenuates chronic liver injury induced by mercuric chloride via the Nrf2/NF-κB/P53 signaling pathway in rats. *Oncotarget.* 8, 25, 40982-40993